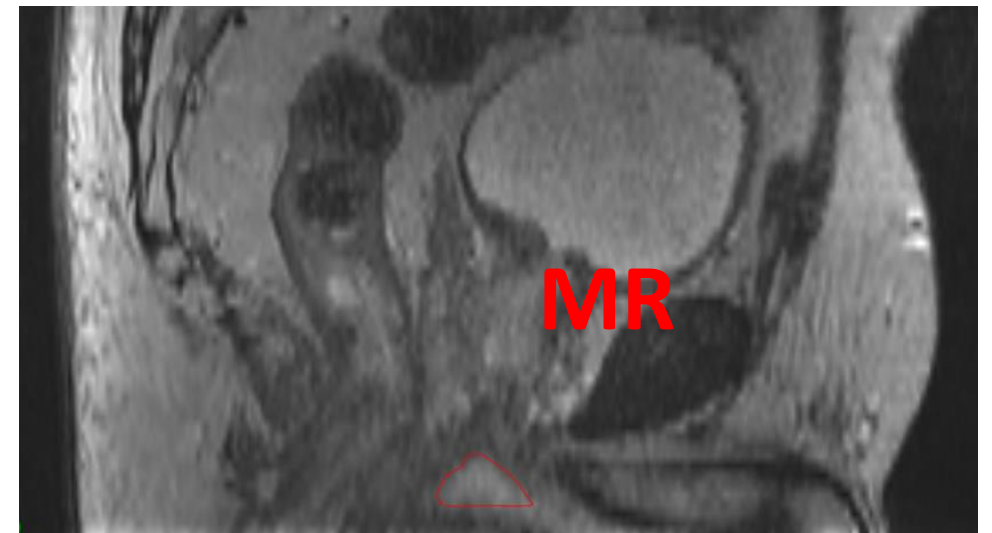
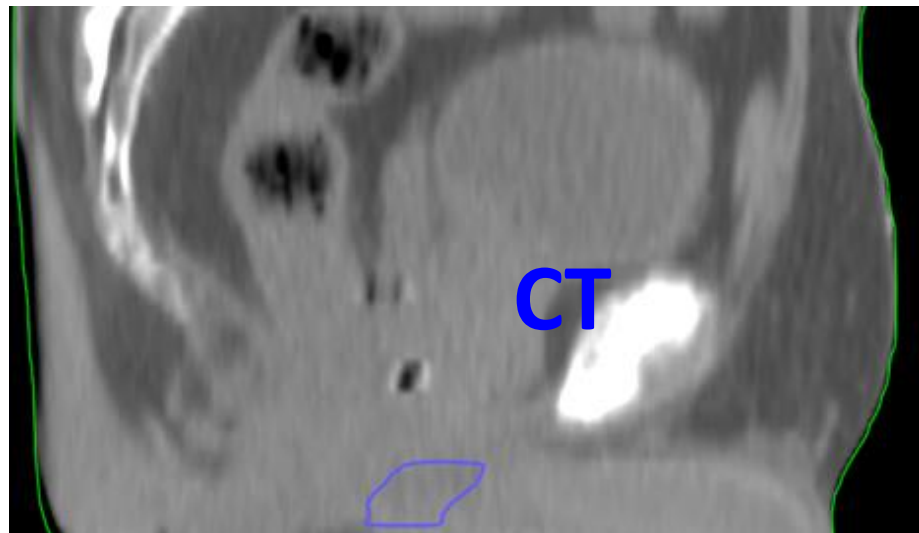


Inritningsmanual STRÅNG-projektet

Penisbulben, v. 2019-05-08



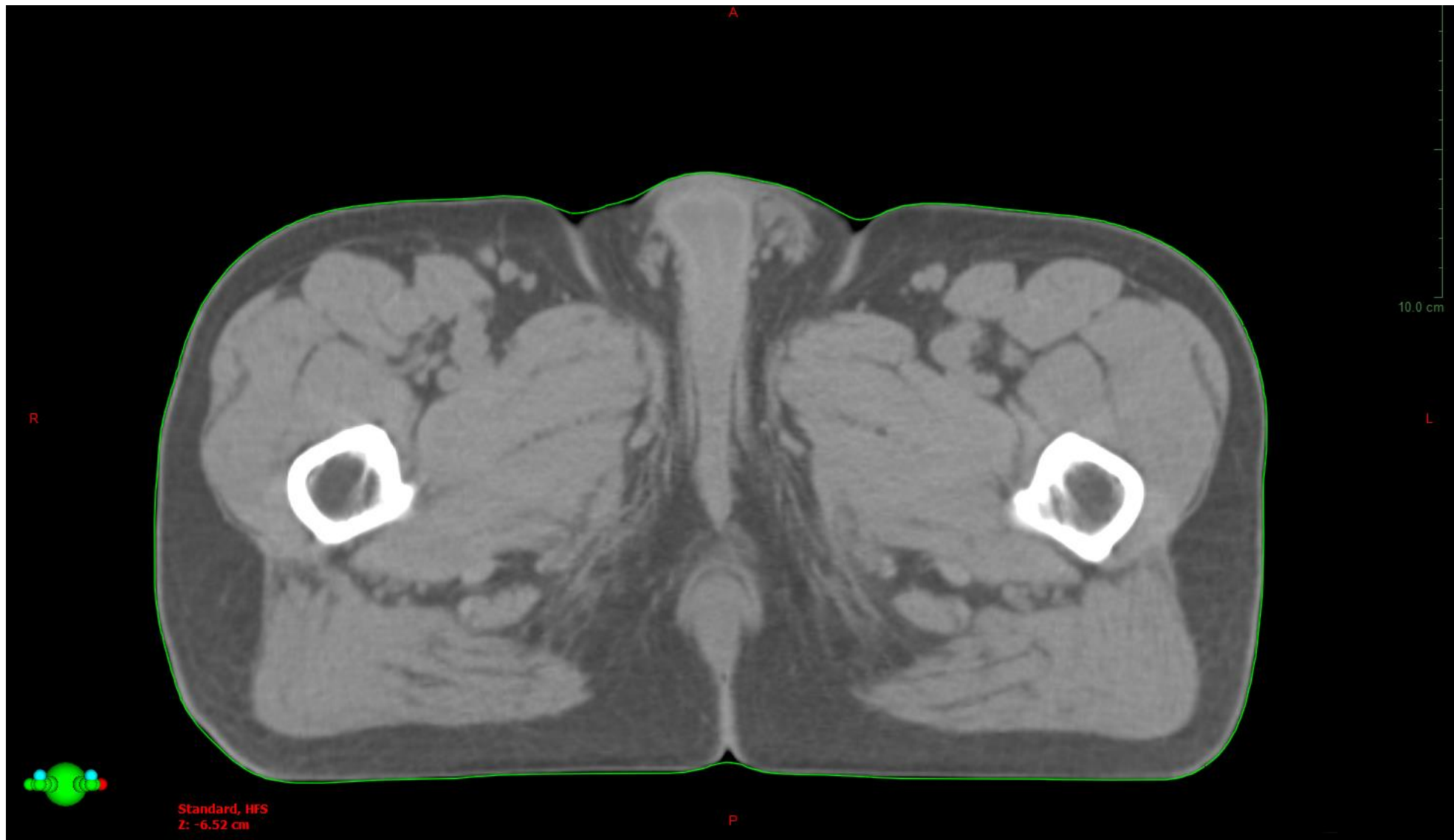
Anatomiska begränsningar

Standardnamn	Beskrivning	Svensk översättning	ANATOMISKA BEGRÄNSNINGAR					
			Kraniellt	Kaudalt	Medialt	Lateralt	Ventralt	Dorsalt
PenileBulb	En del av manliga genitalia; oval/rund medellinjesstruktur belägen i botten mellan penis svällkroppar	Penisbulben	Diaphragma urogenitale, ungefär 1 cm från apex prostata (MR)	ej aktuellt	ej aktuellt	Crura penis (CT)	Corpora cavernosum och Uretra (CT)	M. levator ani (CT)

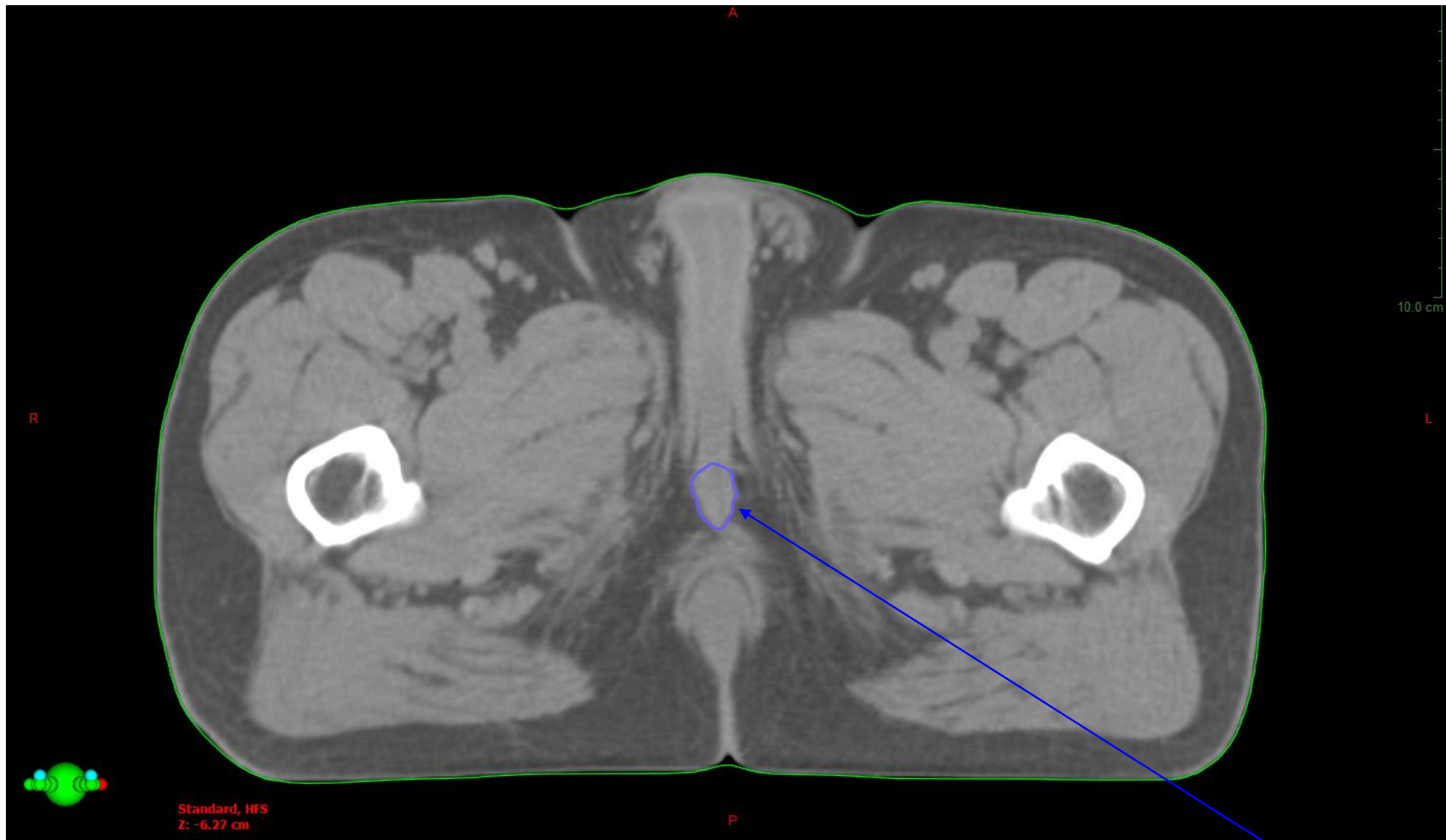
Referenser

1. Wallner KE et al. *Penile bulb imaging*. Int J Radiat Oncol Biol Phys 2002;53:928-33.
2. Gay HA et al. *Pelvic normal tissue contouring guidelines for radiation therapy: A Radiation Therapy Oncology Group consensus panel atlas*. Int J Radiat Oncol Biol Phys 2012;83(3):e353-62.

CT, 120kV
*2.5 mm snitt-
tjocklek*

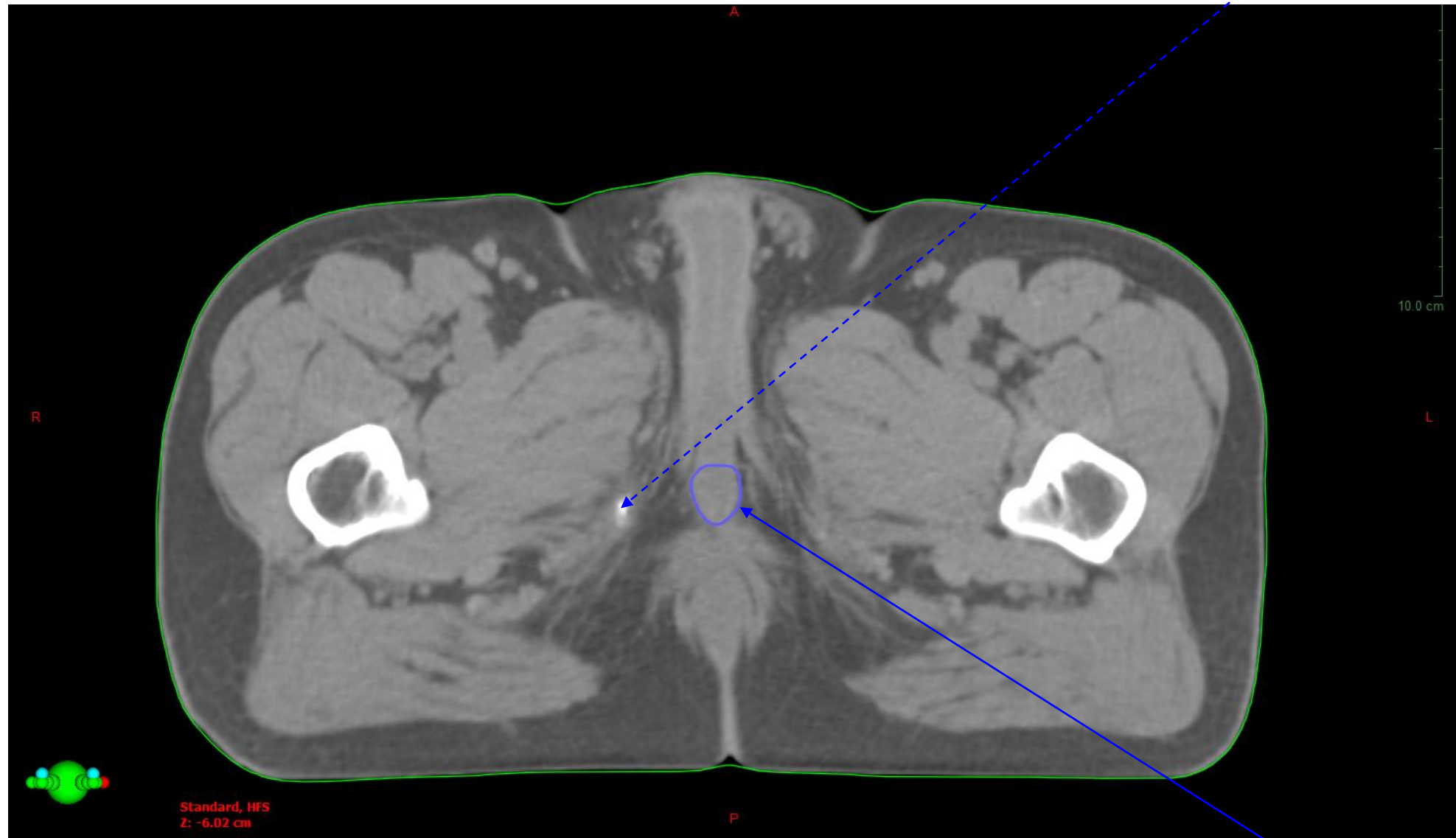


Snitt utanför kaudal penisbulbgräns



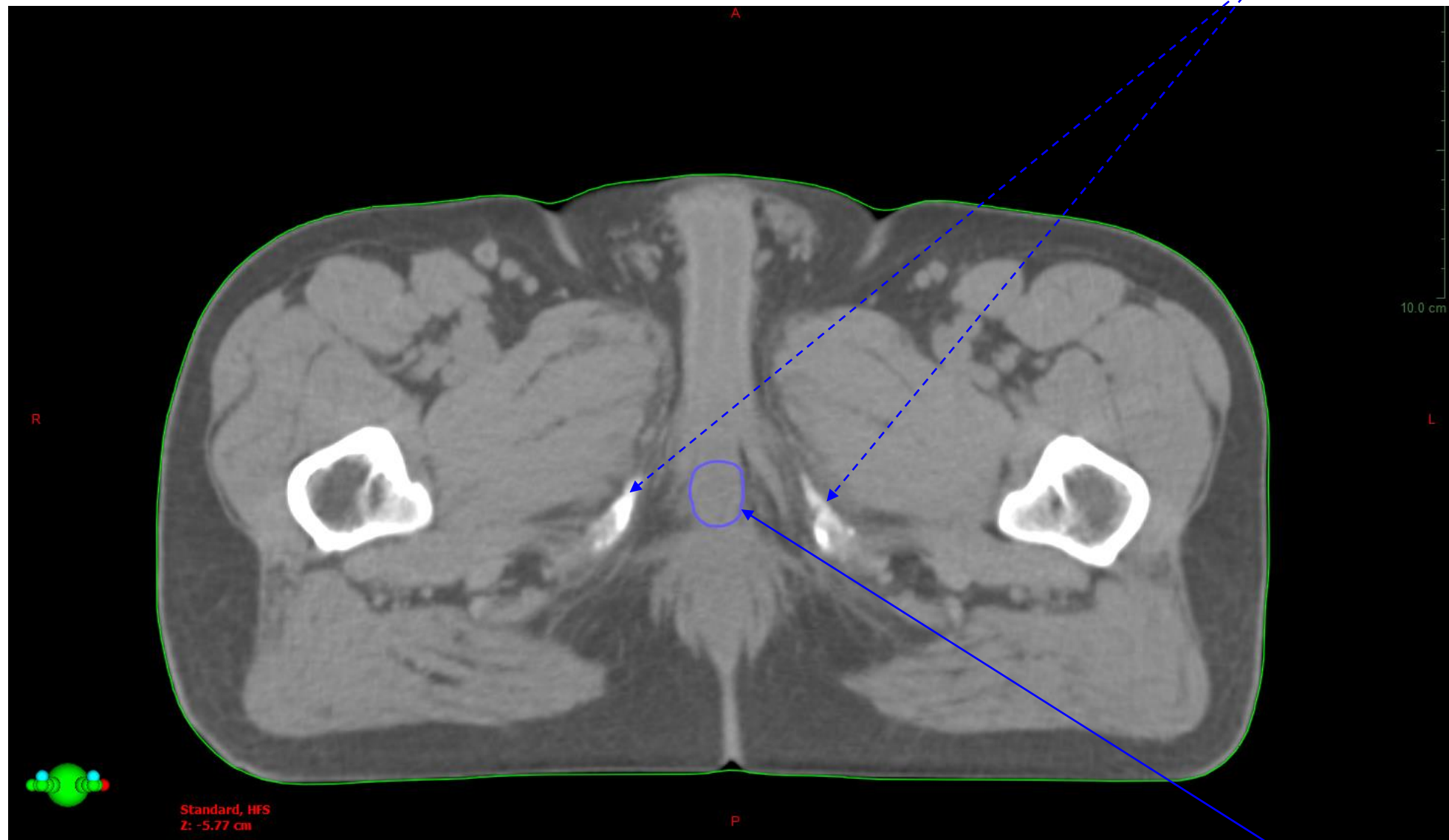
Penisbulb, kaudal gräns

Ischial tuberosities (dx), mest kaudala snittet

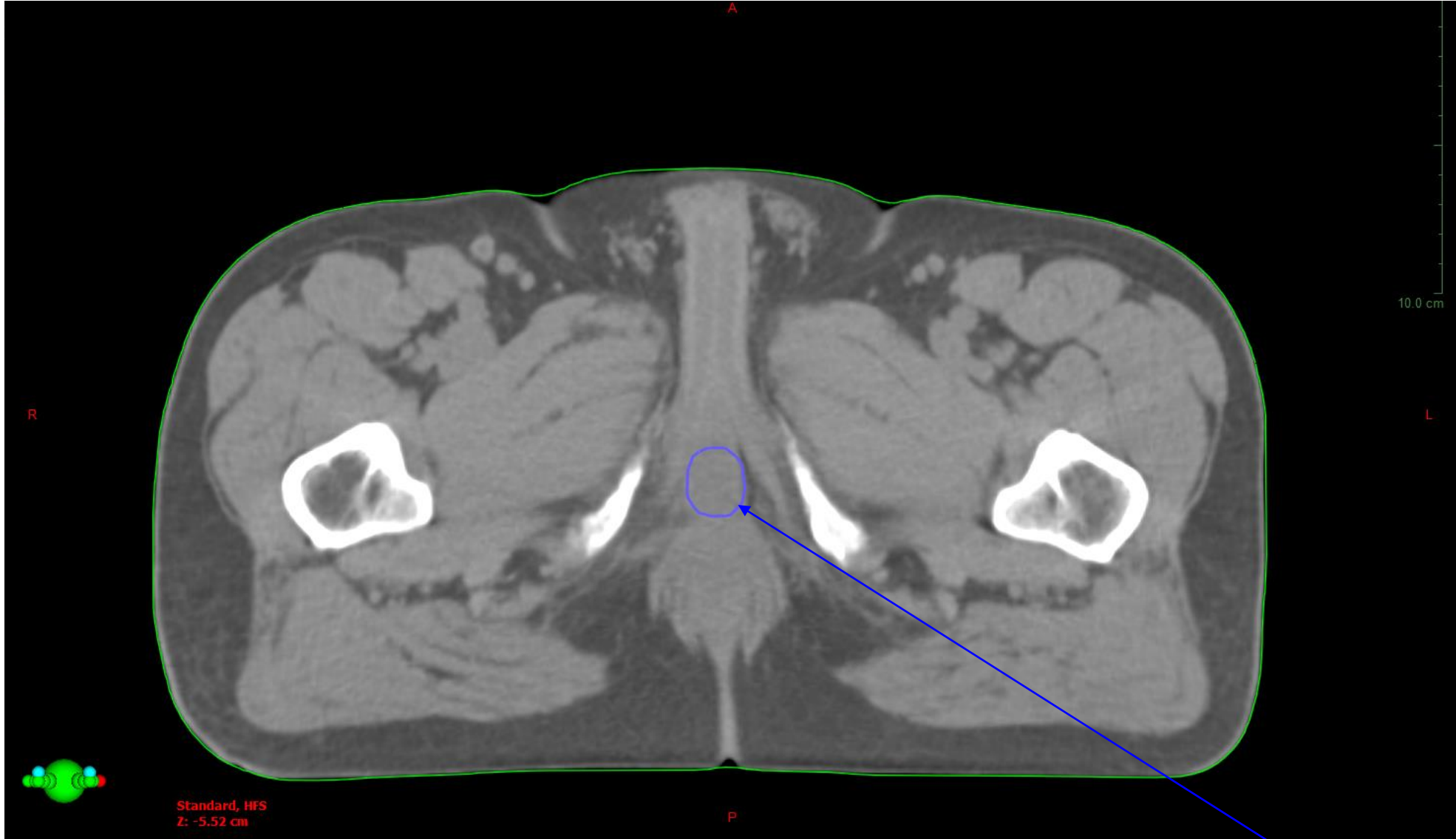


Penisbulb

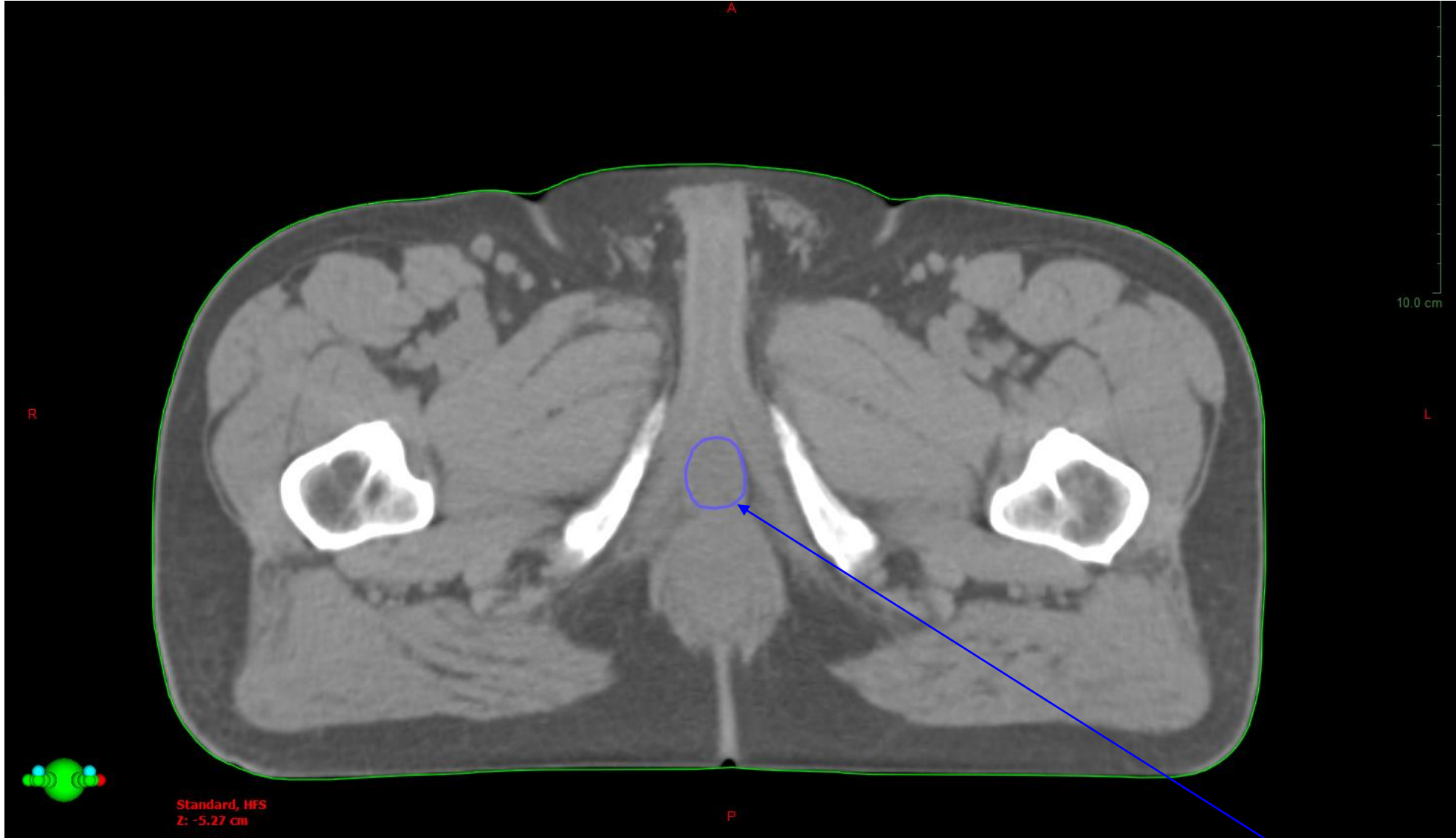Ischial tuberosities



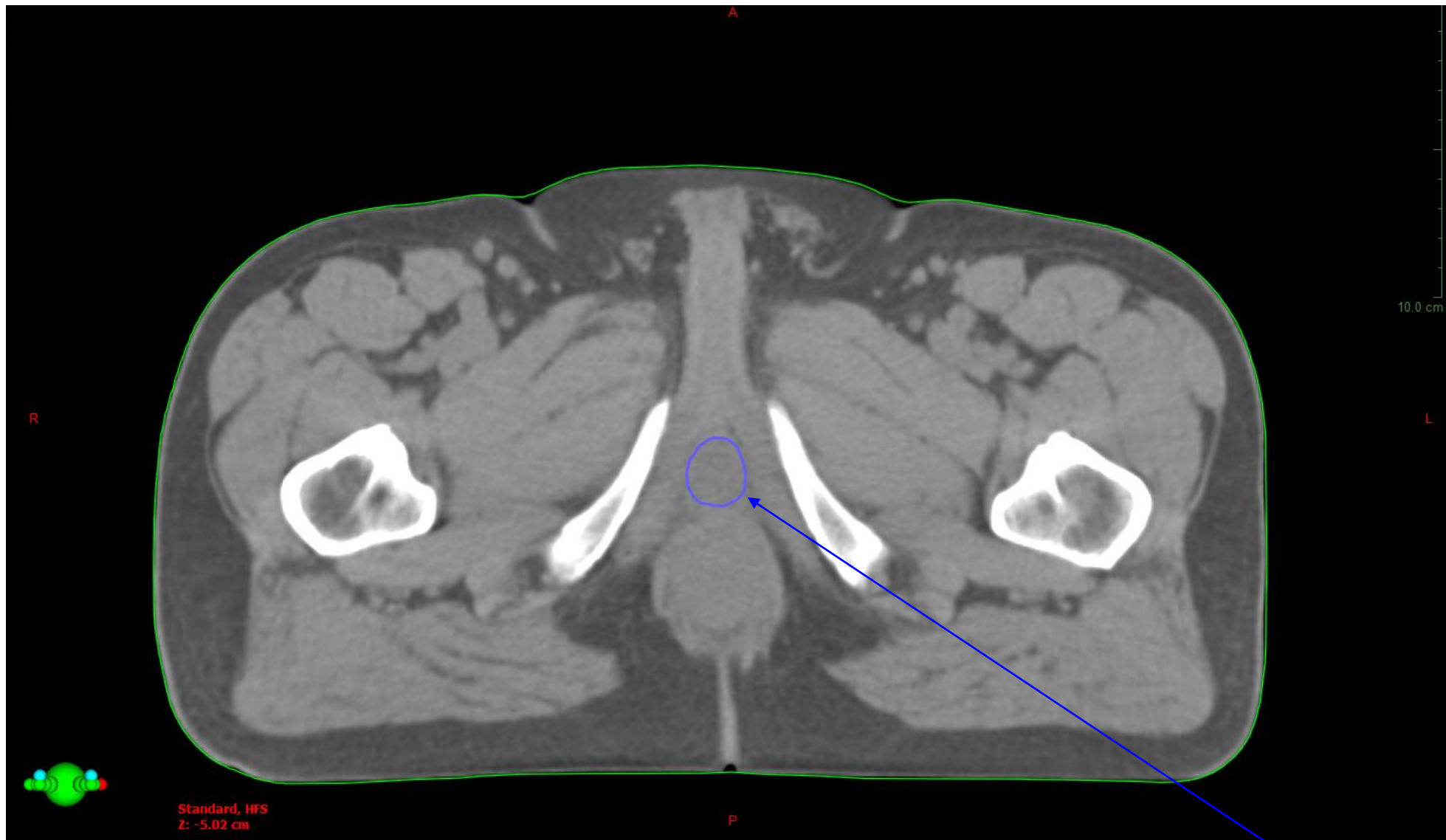
Penisbulb



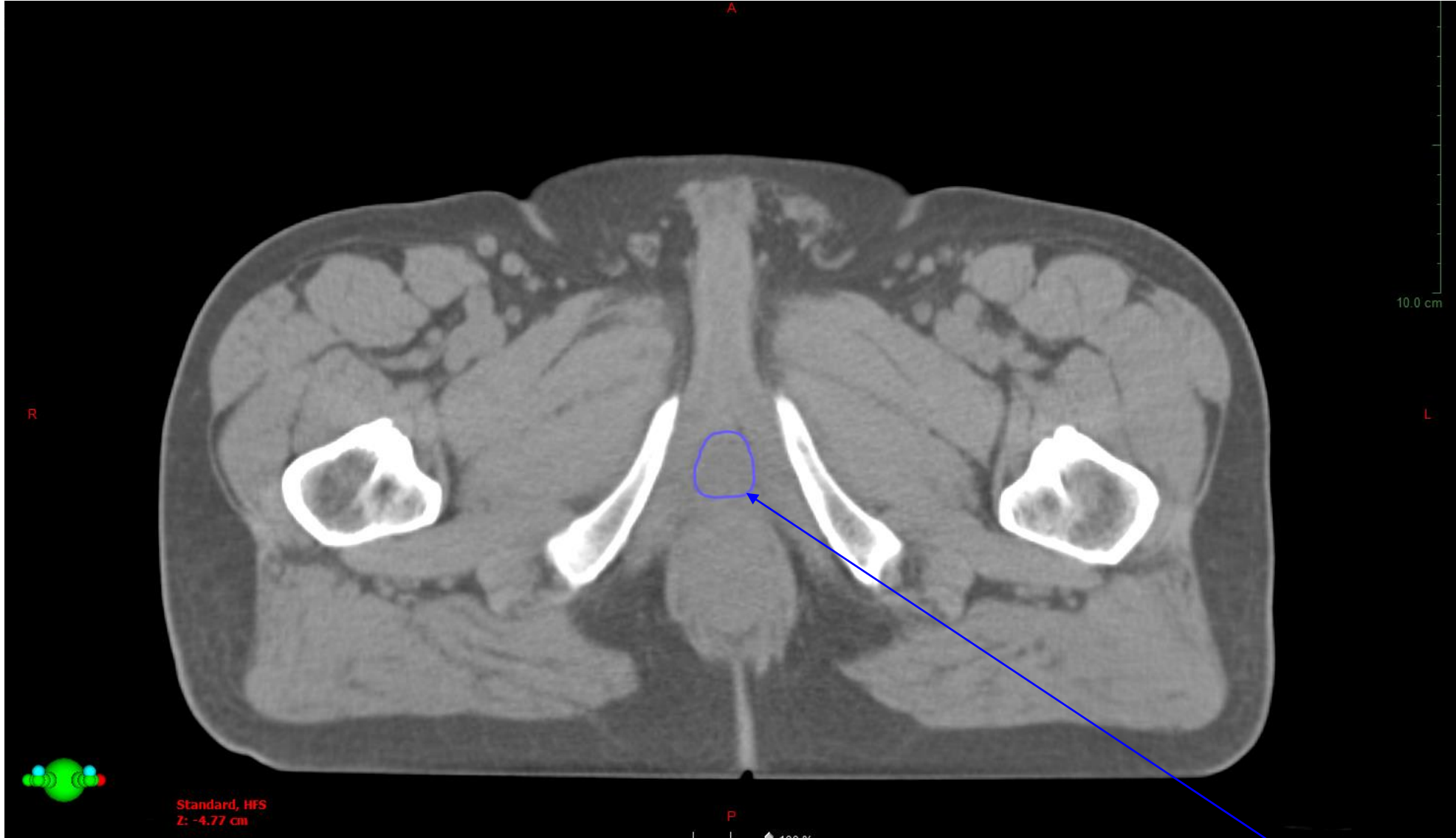Penisbulb



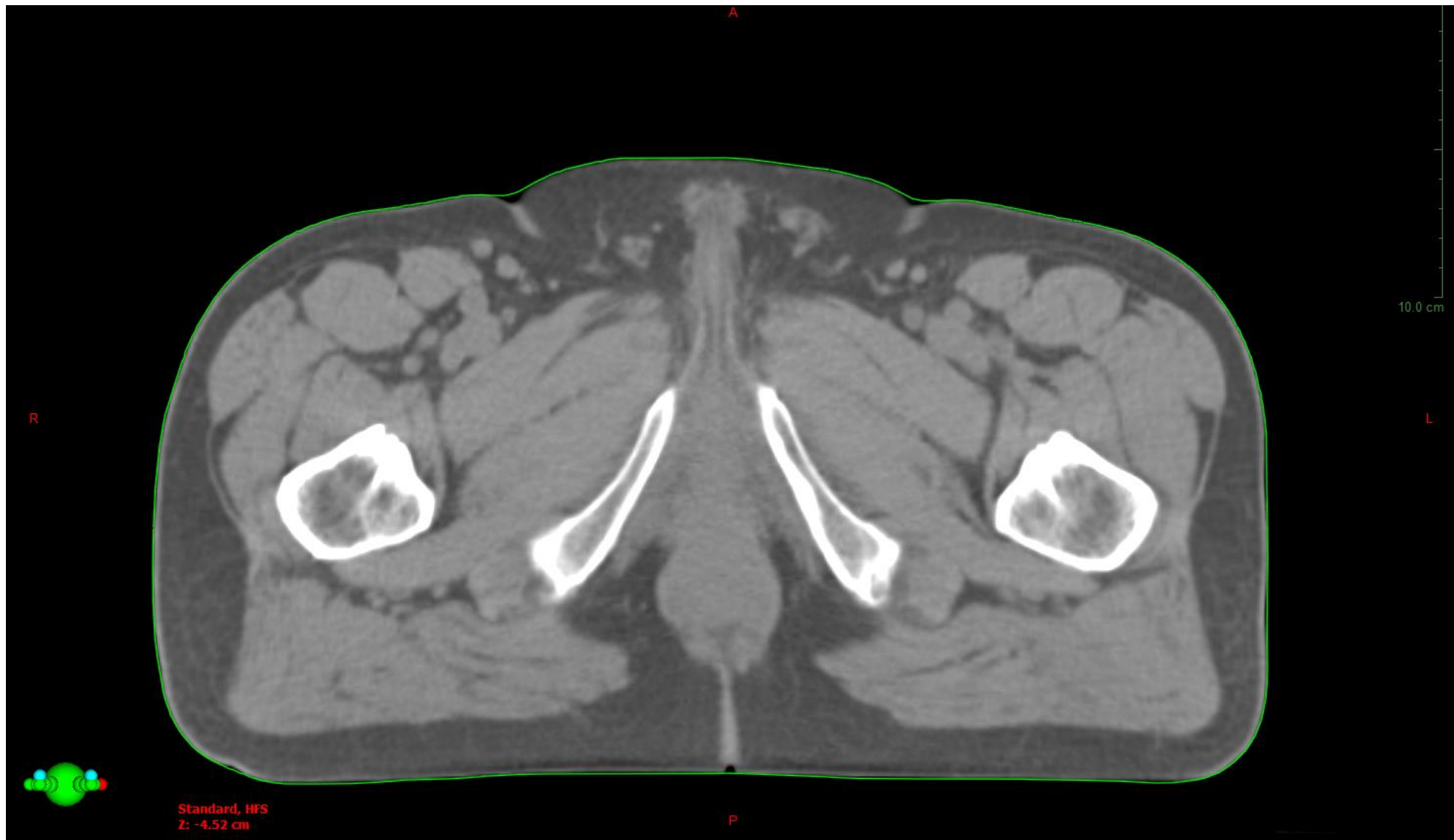
Penisbulb



Penisbulb, kranial gräns

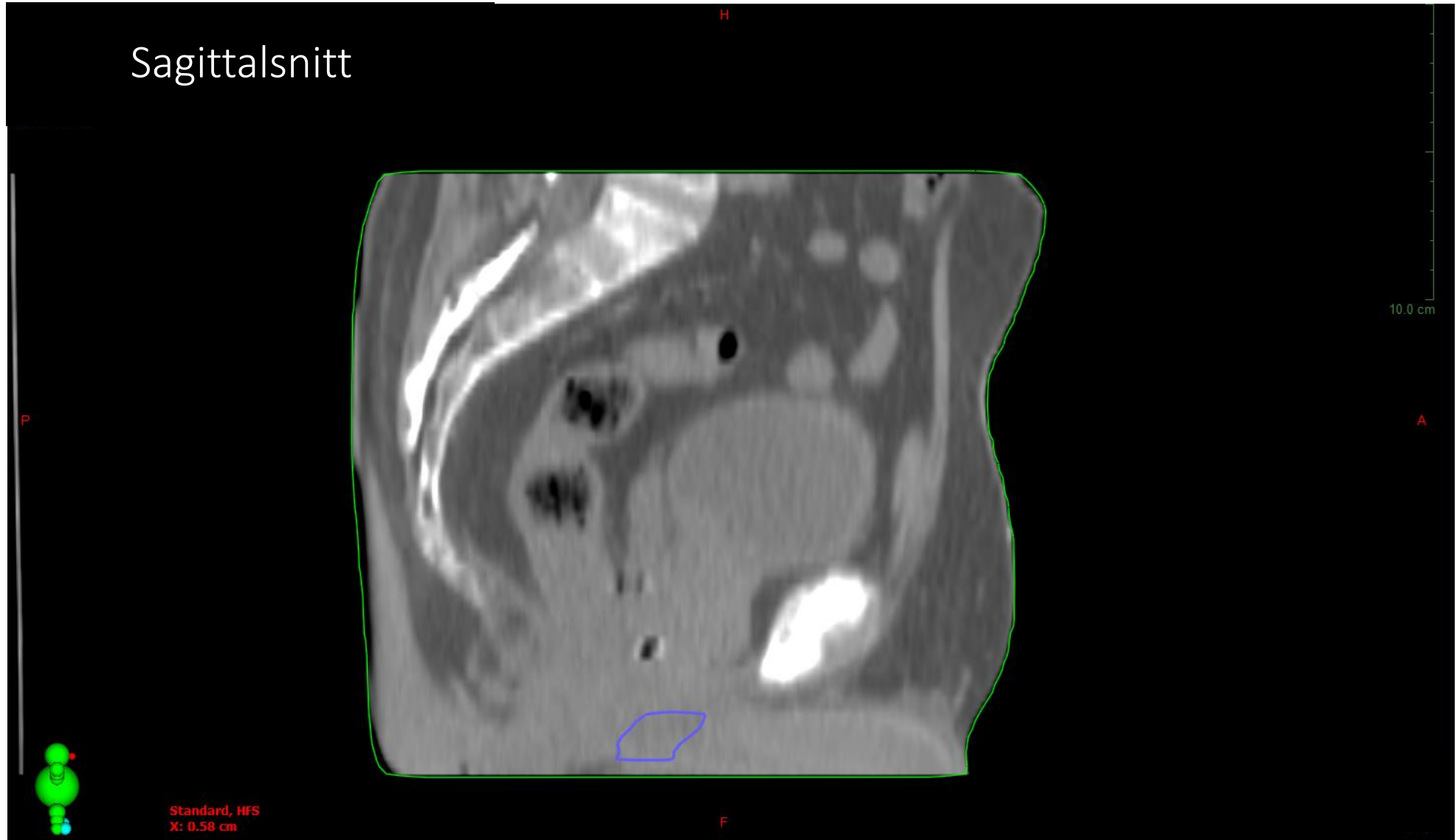


Penisbulb

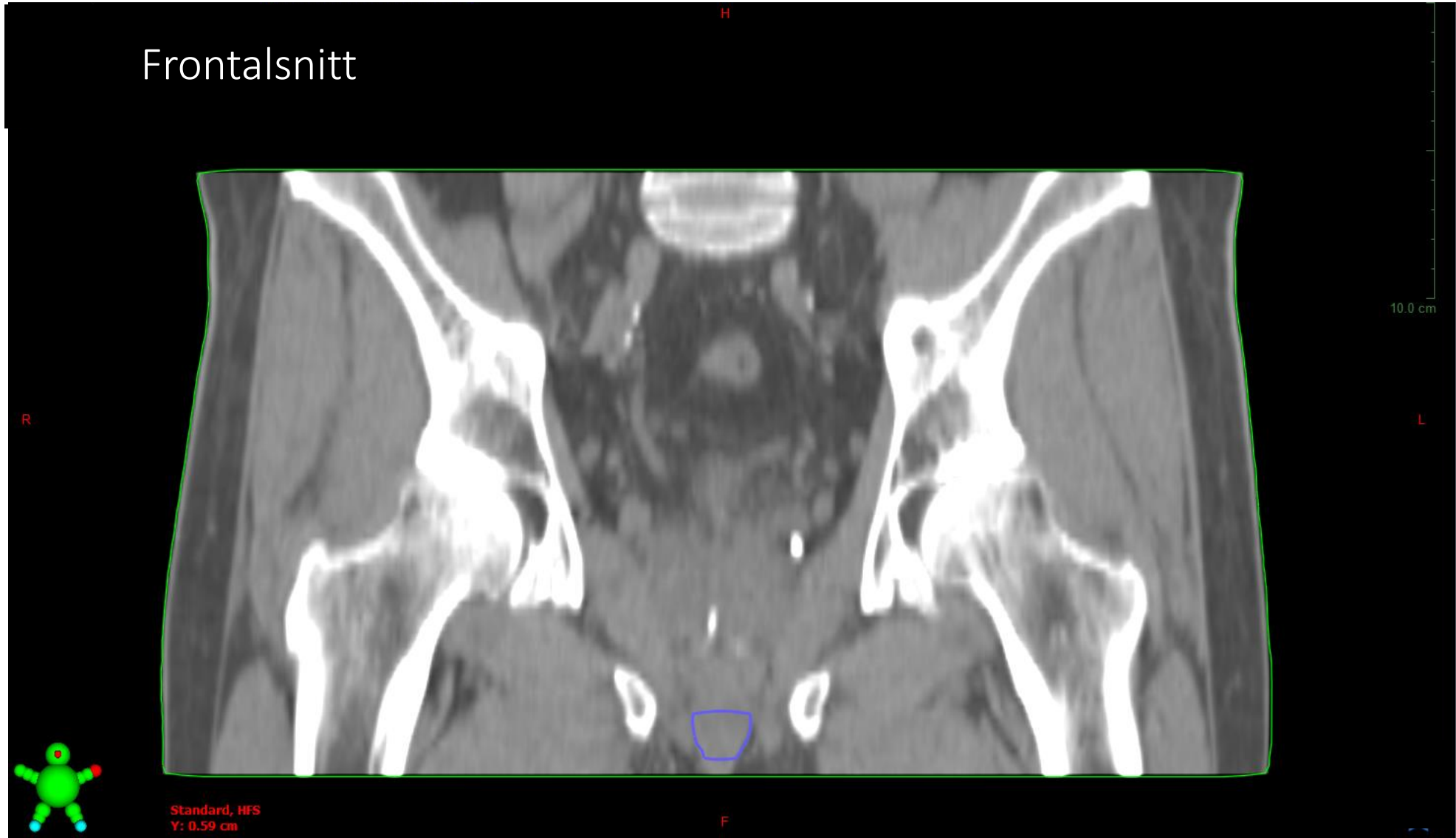


Snitt utanför kranial penisbulbgräns

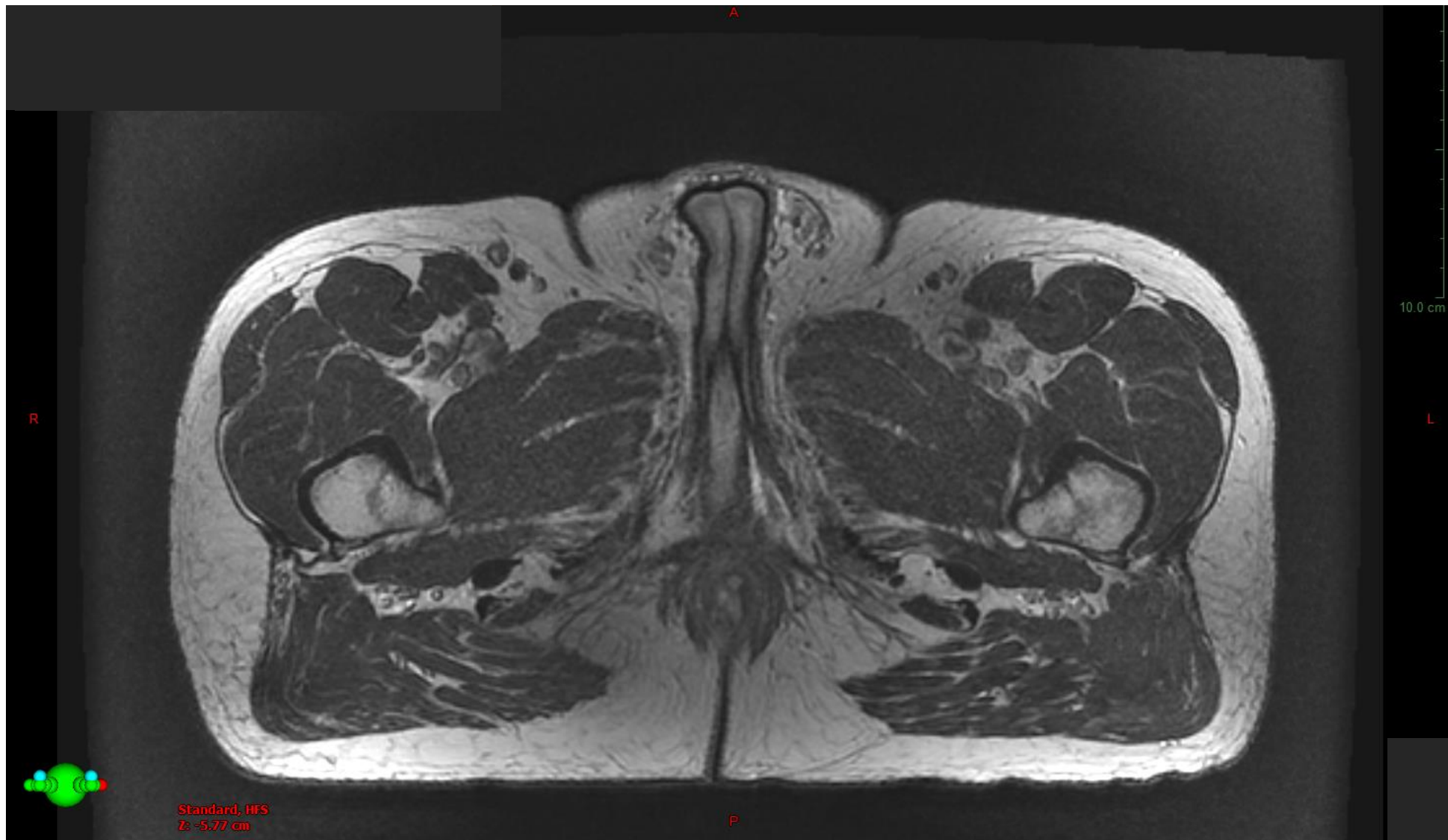
Sagittalsnitt



Frontalschnitt

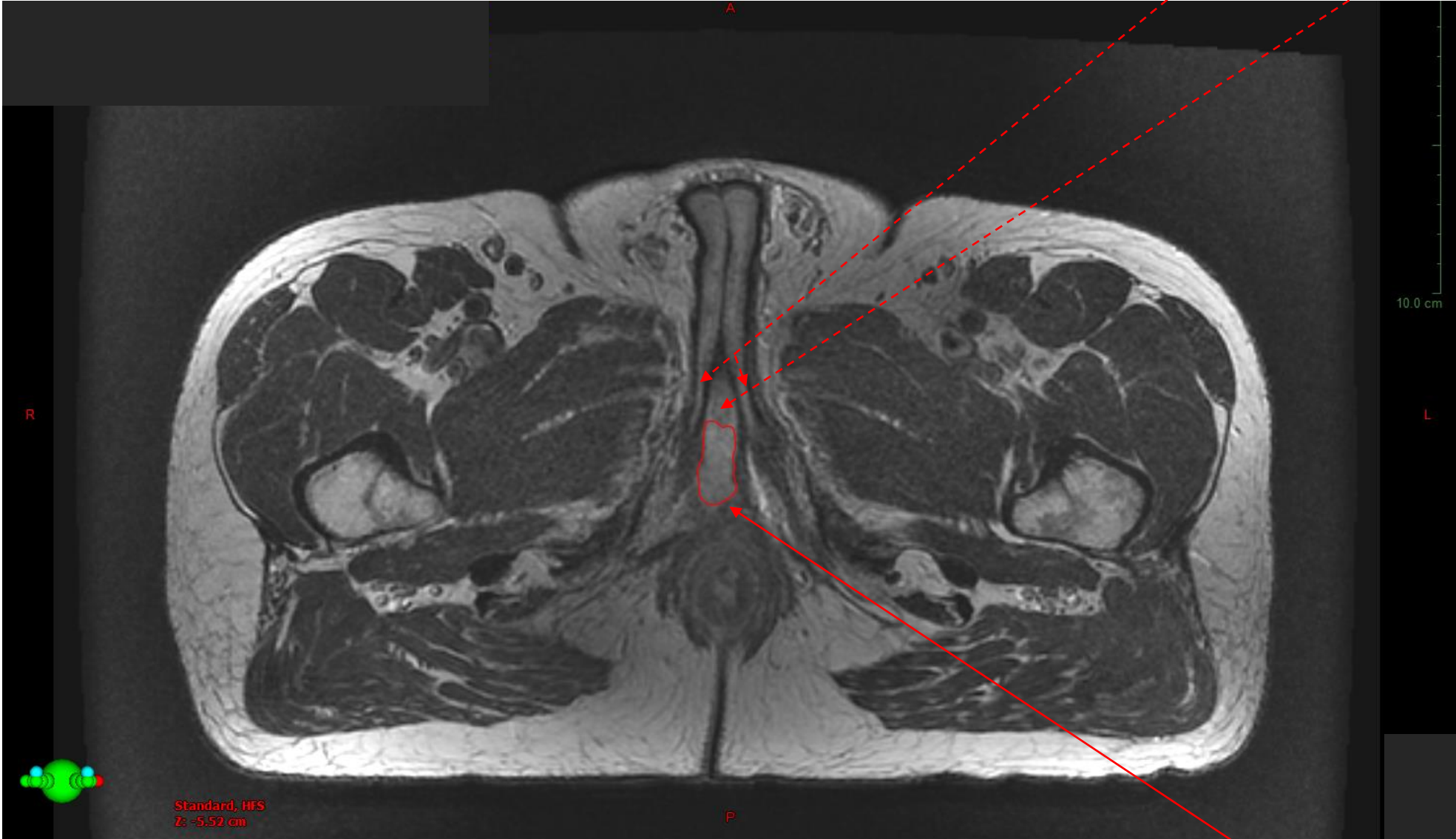


MR, 3T
*2.5 mm snitt-
tjocklek*



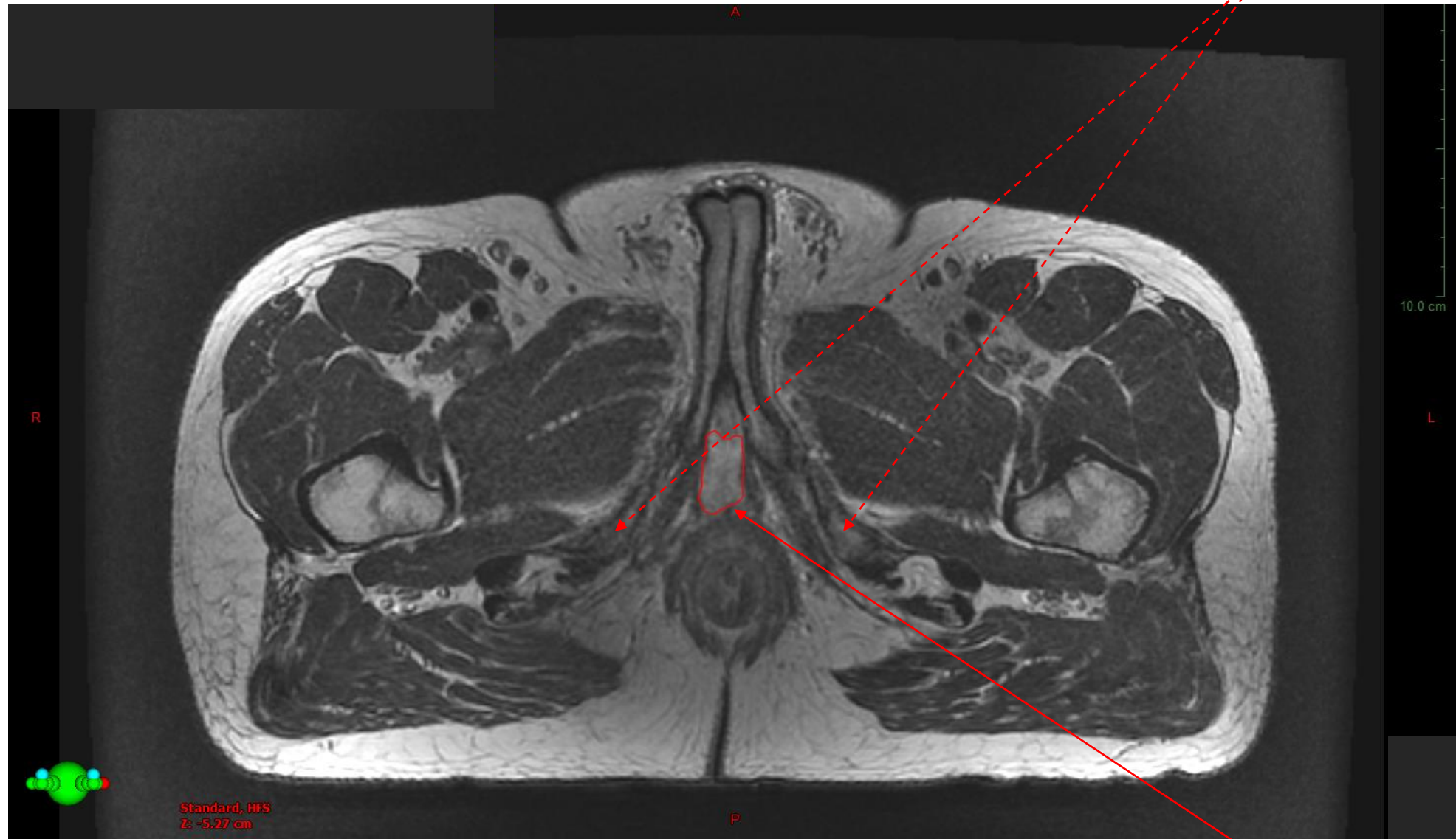
Snitt utanför kaudal penisbulbgräns

Crura Penis Uretra



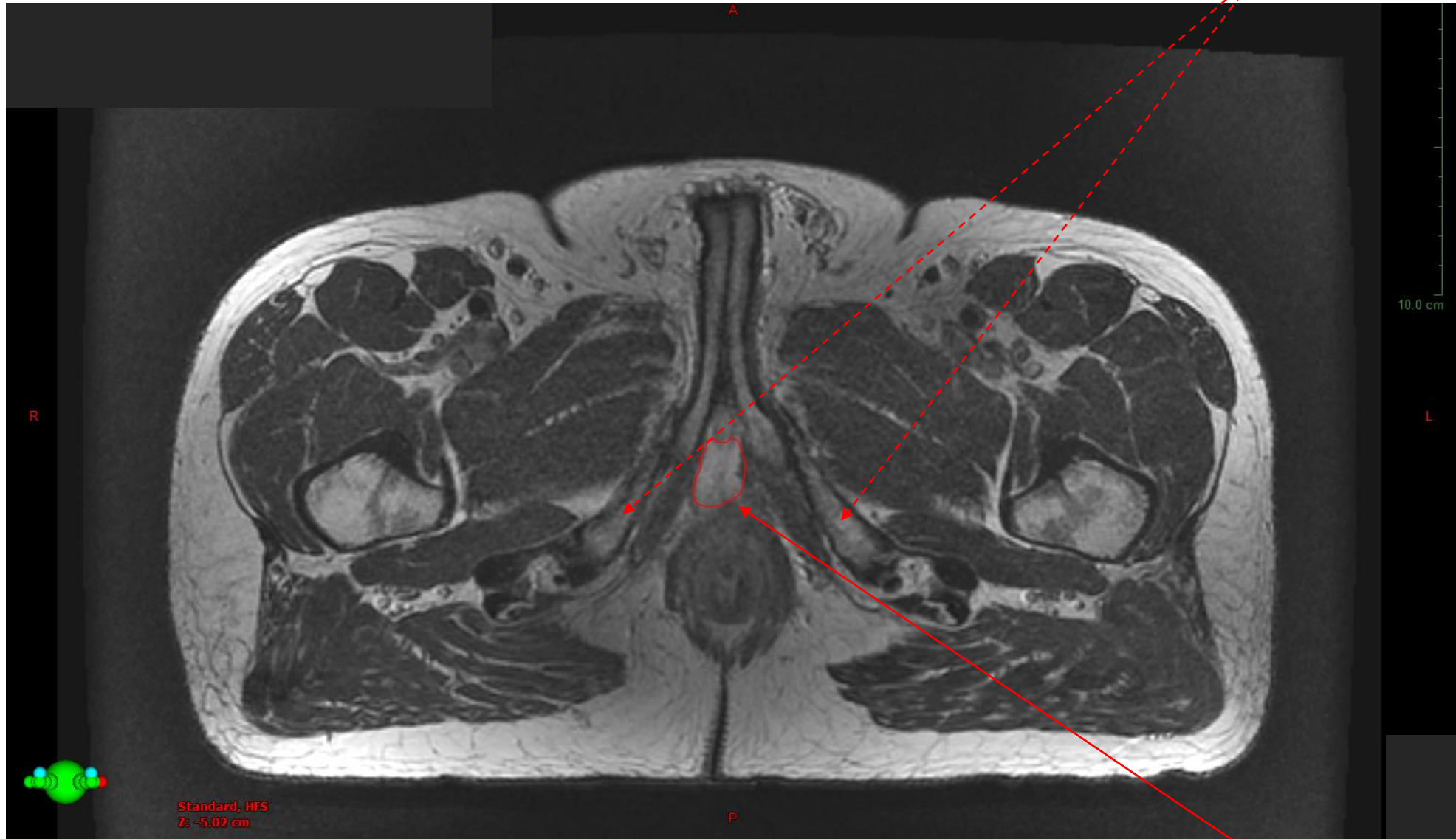
Penisbulb, kaudal gräns

Ischial tuberosities, mest kaudala snittet

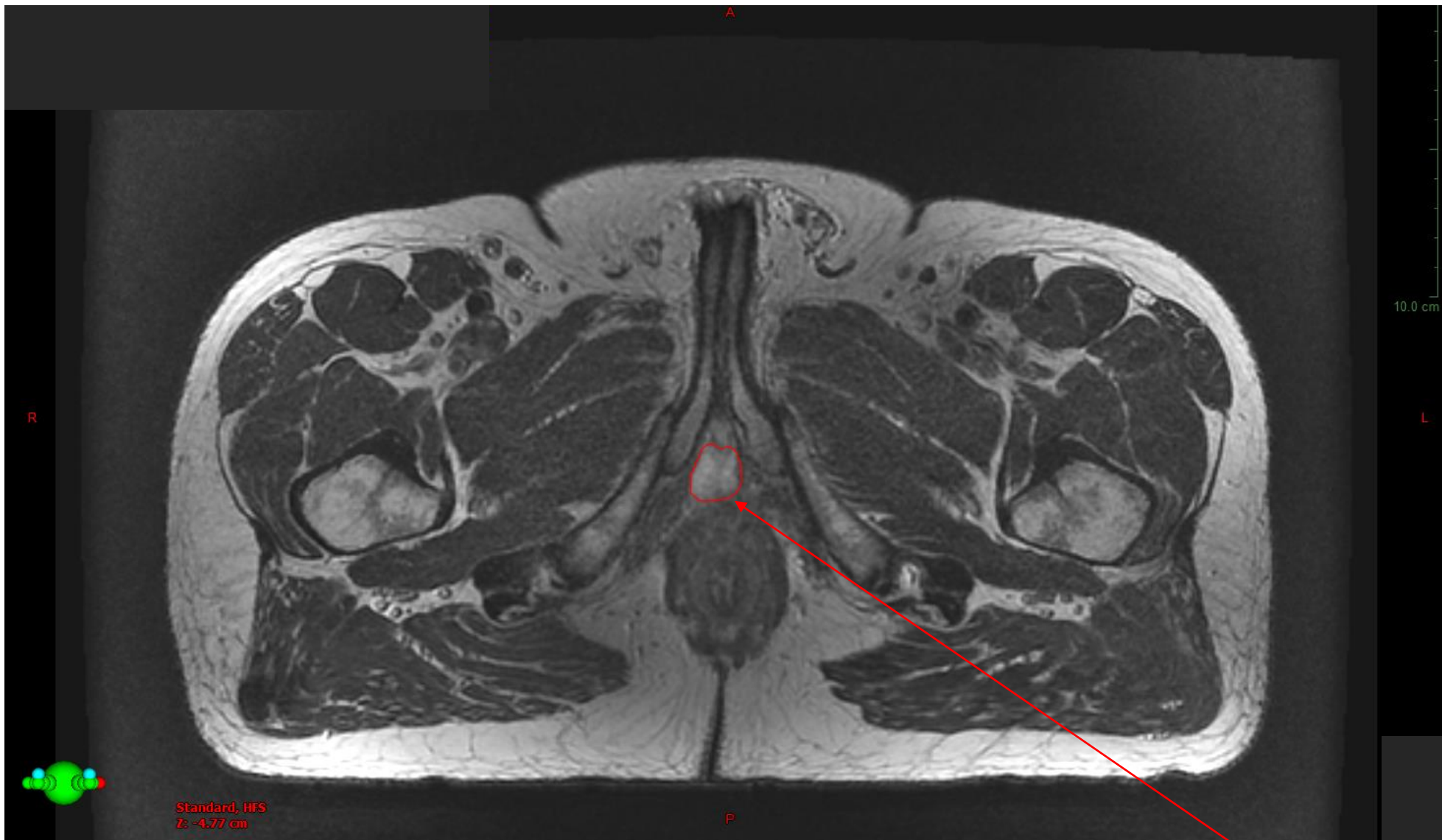


Penisbulb

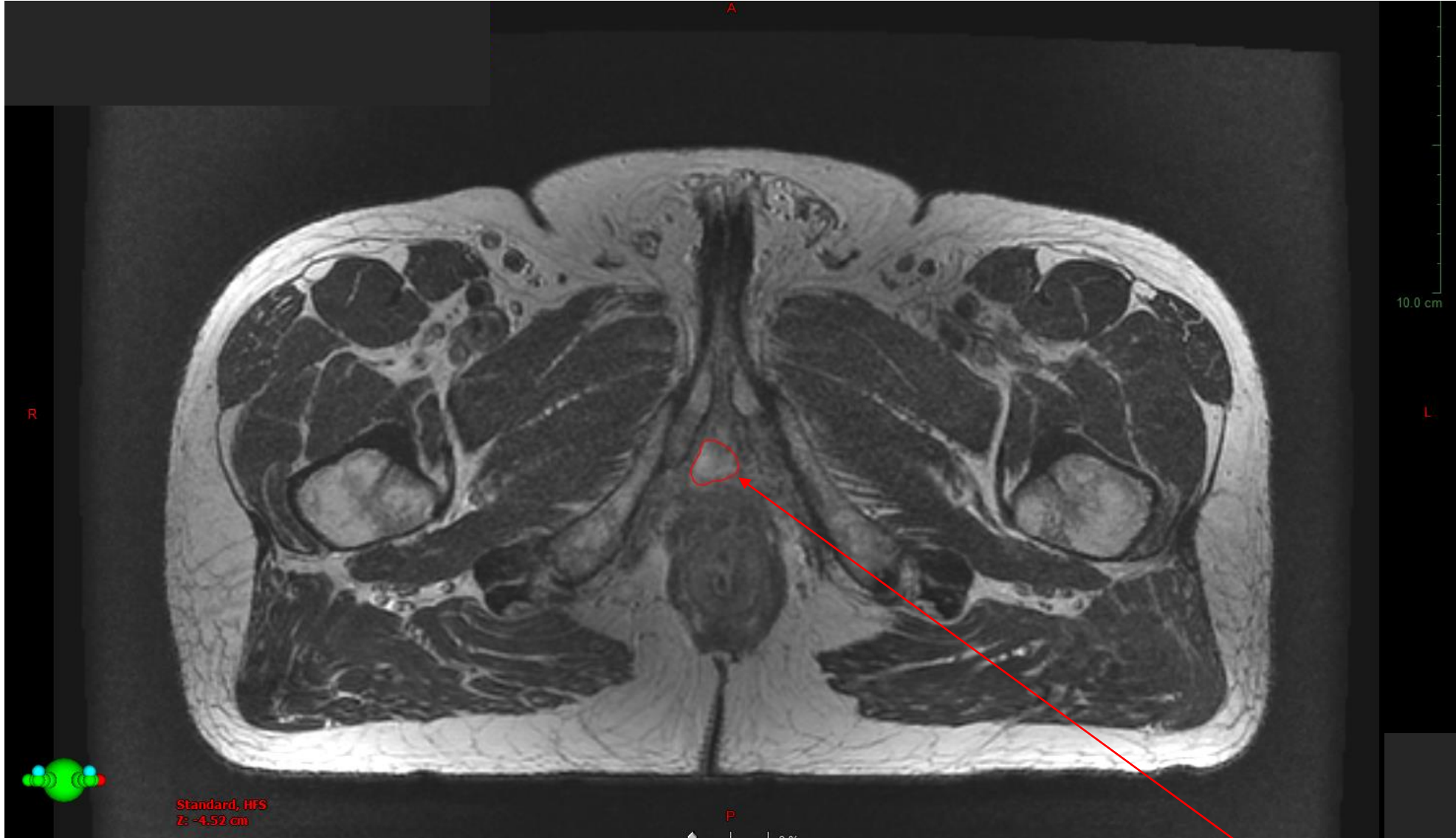
Ischial tuberosities



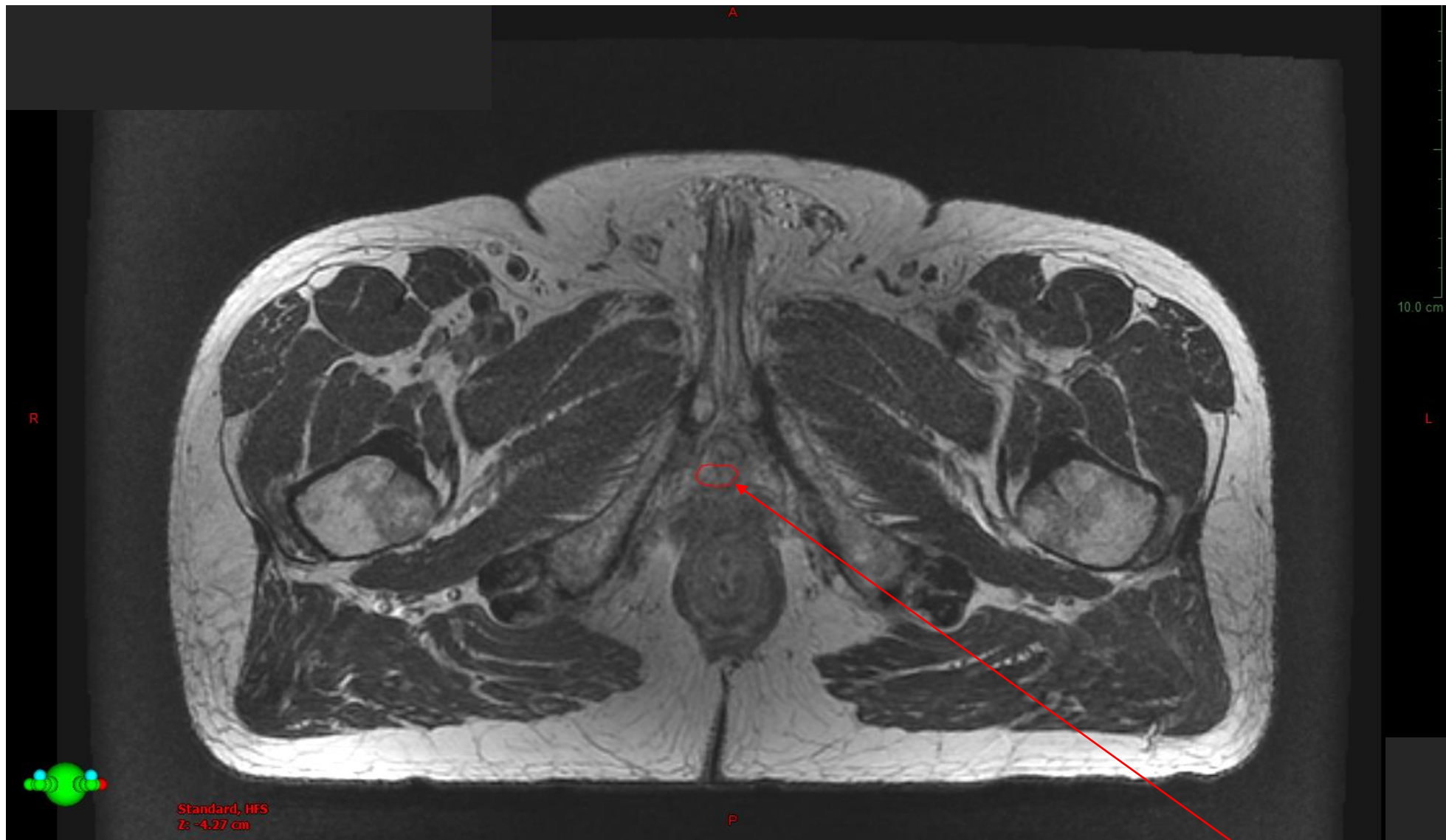
Penisbulb



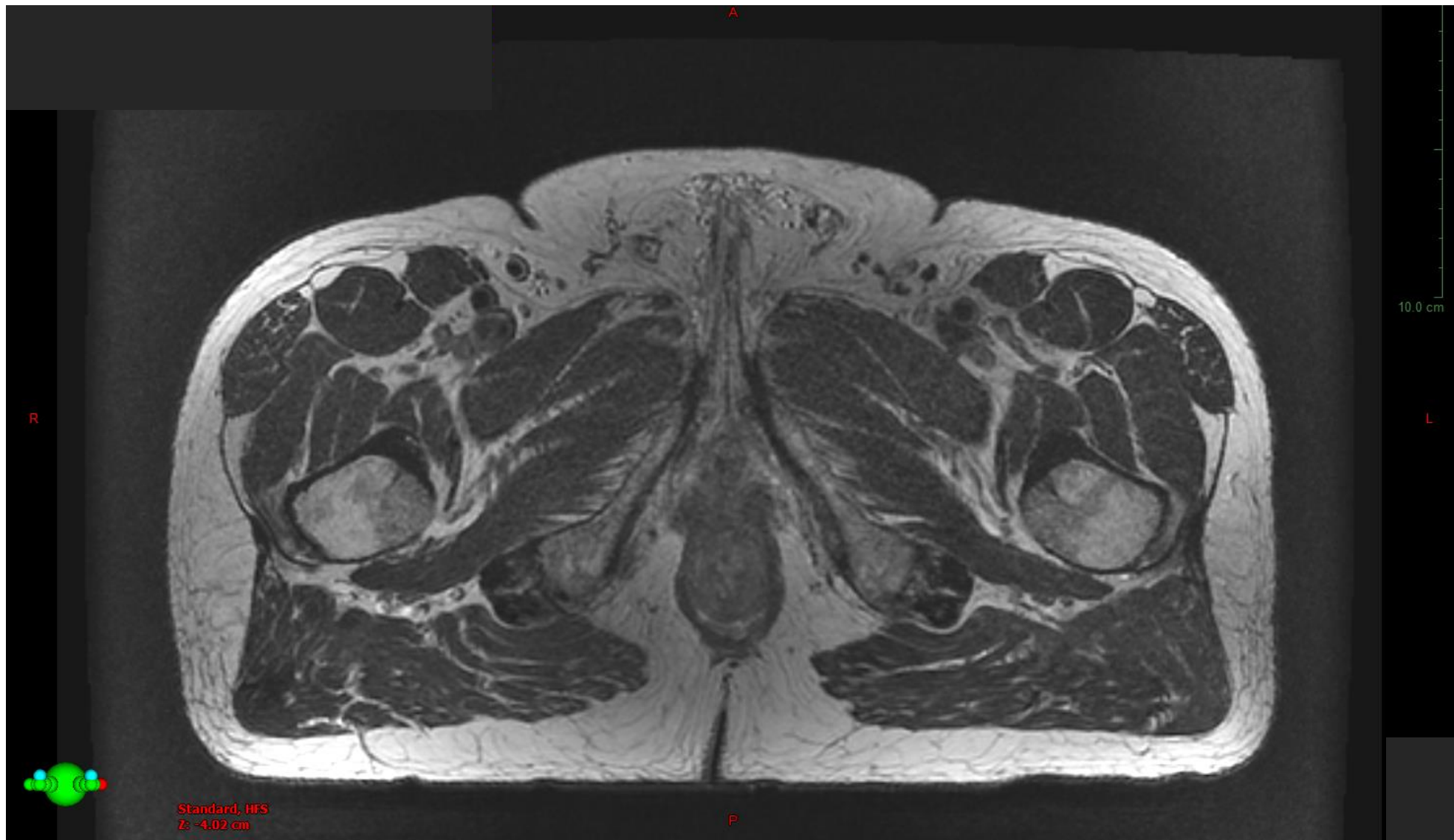
Penisbulb



Penisbulb

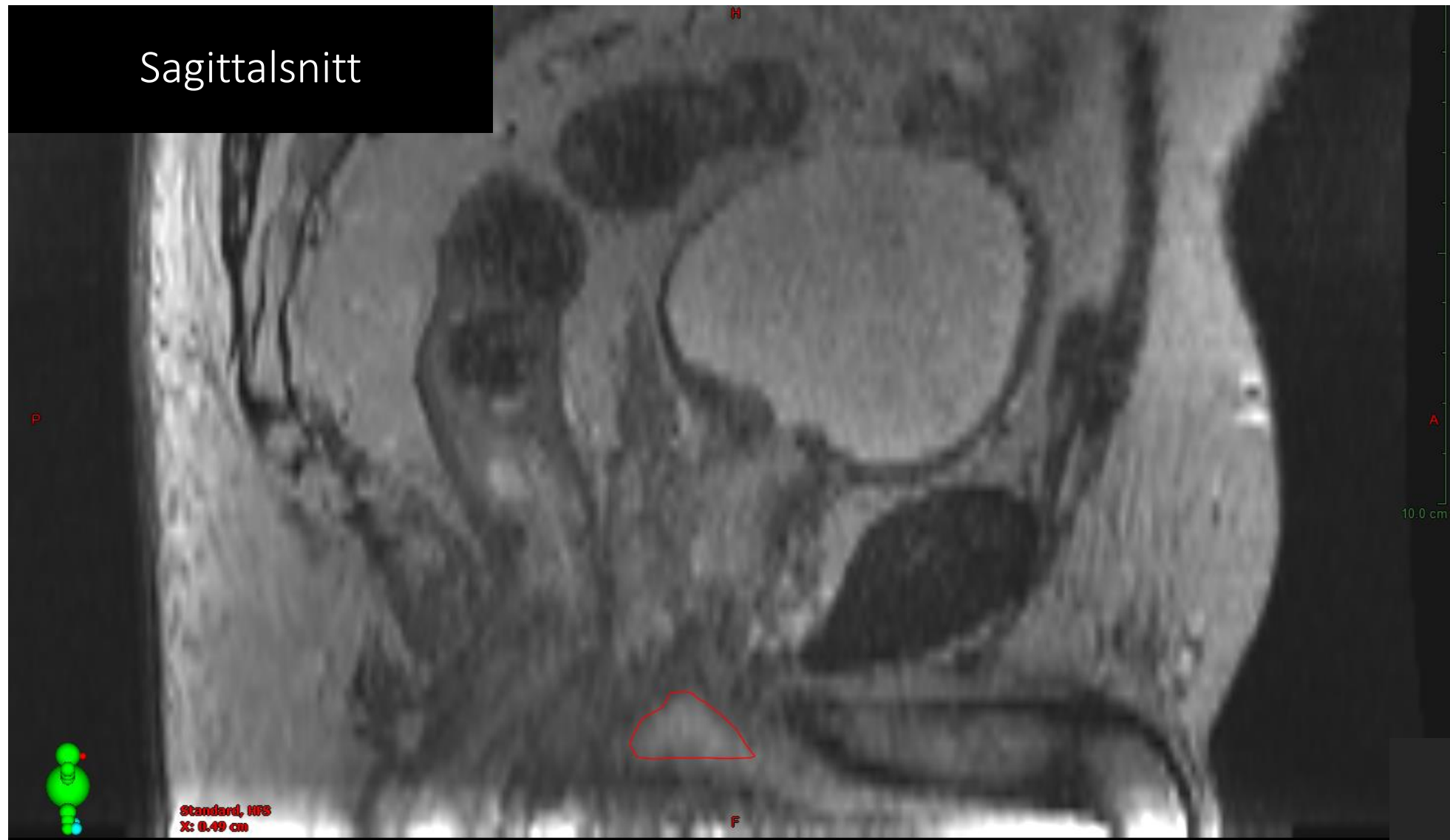


Penisbulb, mest kraniala snittet



Snitt utanför kranial penisbulbgräns

Sagittalsnitt



Frontalschnitt

